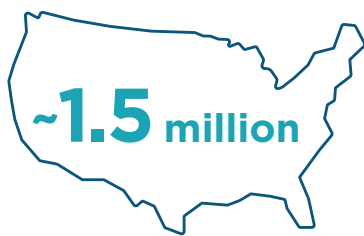

GEOGRAPHIC ATROPHY (GA): By the Numbers

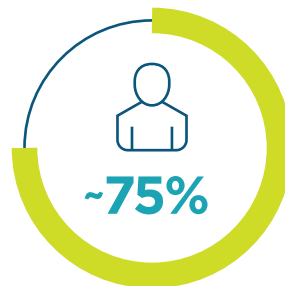SEE **GA** DIFFERENTLY

GA is an advanced form of age-related macular degeneration (AMD) that can cause irreversible vision loss.¹

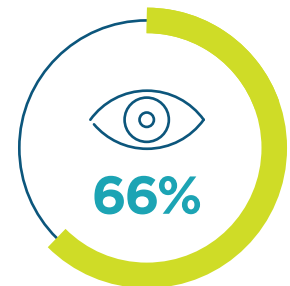
A bigger burden than you may realize



people in the United States
are currently affected by GA²



of people with GA in the
United States are believed
to be undiagnosed³



of eyes with GA may become
**blind or severely visually
impaired without treatment**⁴

Anyone can be affected

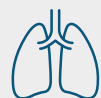These risk factors increase the likelihood of GA, but it can occur in any patient:



Age \geq 55 years⁵



Caucasian descent⁶



Active smoker⁶⁻⁹

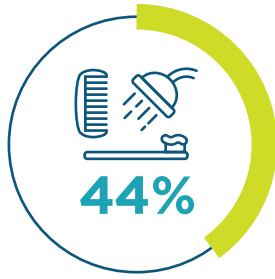

Hypertension/CVD^{6,7}

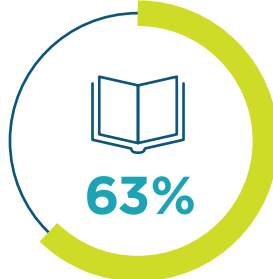

High-fat diet⁵

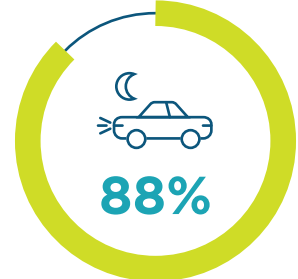Patients lose more than just vision



require assistance with daily activities¹⁰

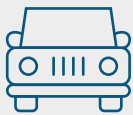

report difficulty reading¹¹



lose confidence driving at night¹⁰

Impacts patients faster than you think

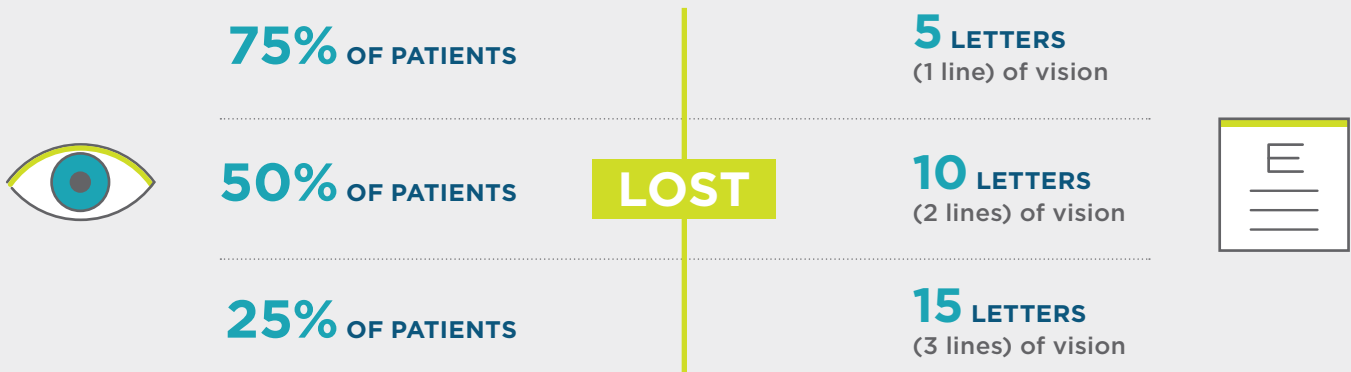

In **1.6 years** after diagnosis, **67%** of people with GA lose their ability to drive¹²

Extrafoveal lesions can progress to foveal involvement in **2.5 years**¹³



2 years after enrollment in a GA study¹⁴:



Scan here to find more resources created in partnership with the eye care community or visit seeGAdifferently.com/info

CVD=cardiovascular disease.

References: 1. Boyer DS, Schmidt-Erfurth U, van Lookeren Campagne, Henry EC, Brittain C. The pathophysiology of geographic atrophy secondary to age-related macular degeneration and the complement pathway as a therapeutic target. *Retina*. 2017;37(5):819-835. 2. Jaffe GJ, Westby K, Csaky KG, et al. *Ophthalmology*. 2021;128(4):576-586. 3. IQVIA Medical Claims (Dx) Data Jan20-Dec21: 24 Months. 4. Colijn JM, Liefers B, Joachim N, et al. Enlargement of geographic atrophy from first diagnosis to end of life. *JAMA Ophthalmol*. 2021;139(7):743-750. 5. Flaxel CJ, Adelman RA, Bailey ST, et al. Age-related macular degeneration Preferred Practice Pattern®. *Ophthalmology*. 2020;127(1):P1-P65. 6. Veilla S, Garcia-Medina JJ, Garcia-Layana A, et al. Smoking and age-related macular degeneration: review and update. *J Ophthalmol*. 2013;2013:895147. 7. Holz FG, Strauss EC, Schmitz-Vaickenberg S, van Lookeren Campagne M. Geographic atrophy: clinical features and potential therapeutic approaches. *Ophthalmology*. 2014;121(5):1079-1091. 8. Heesterbeek TJ, Lores-Motta L, Hoyng CB, Lechanteur YTE, den Hollander AL. Risk factors for progression of age-related macular degeneration. *Ophthalmic Physiol Opt*. 2020;40(2):140-170. 9. Sadda SR, Chakravarthy U, Birch DG, Staurenghi G, Henry EC, Brittain C. Clinical endpoints for the study of geographic atrophy secondary to age-related macular degeneration. *Retina*. 2016;36(10):1806-1822. 10. Patel PJ, Ziemssen F, Ng E, et al. Burden of illness in geographic atrophy: a study of vision-related quality of life and health care resource use. *Clin Ophthalmol*. 2020;14:15-28. 11. Singh RP, Patel SS, Nielsen JS, Schmier JK, Rajput Y. Patient-, caregiver-, and eye care professional-reported burden of geographic atrophy secondary to age-related macular degeneration. *Am J Ophthalmol Clin Trials*. 2019;2(1):1-6. 12. Chakravarthy U, Bailey CC, Johnston RL, et al. Characterizing disease burden and progression of geographic atrophy secondary to age-related macular degeneration. *Ophthalmology*. 2018;125(6):842-849. 13. Lindblad AS, Lloyd PC, Clemons TE, et al. Change in area of geographic atrophy in the Age-Related Eye Disease Study: AREDS report number 26. *Arch Ophthalmol*. 2009;127(9):1168-1174. 14. Chakravarthy U, Anegondi N, Steffen V, Ferrara D. Visual functional loss in geographic atrophy (GA): learnings from lampalizumab trial data. Presented at: The Macula Society 46th Annual Meeting; February 15-18, 2023; Miami, FL.



Copyright © 2024 Astellas Pharma Inc. or its affiliates. All trademarks are the property of their respective owners. US-GA-2300066-v1 03/24